

Conservative Management of Anterior Abdominal Penetrating Trauma

Shahram Paydar¹; Parsa Ravanfar^{1,*}; Vahid Shakoori¹

¹Trauma Research Center, Shiraz University of Medical Sciences, Shiraz, IR Iran

*Corresponding author: Parsa Ravanfar, Trauma Research Center, Shiraz University of Medical Sciences, Shiraz, IR Iran. Tel: +98-9393039324, Fax: +98-7136293620, E-mail: ravanfarpa@yahoo.com

Received: December 1, 2014; Accepted: December 1, 2014

Background: Selective conservative management of abdominal penetrating trauma can significantly minimize the morbidity and length of hospitalization by decreasing the rate of unnecessary laparotomies.

Objectives: In the present study, we reported the outcome of newest guidelines of our trauma center in one year.

Patients and Methods: All patients with anterior abdominal stab wounds who were referred to Rajaiee trauma center between September 2012 and September 2013 were enrolled. Patients without shock, peritonitis, and evisceration who did not require emergency operation were planned for nonoperative management with serial physical examinations, blood cells count, and radiographic investigations. Outcome of nonoperative management was described in order to reveal the advantages and disadvantages of our current guideline.

Results: Among 45 patients who underwent nonoperative management, 27 cases (60%) required laparotomy due to peritonitis or shock. Rate of unnecessary nontherapeutic operations was 49.2%.

Conclusions: Minimizing diagnostic procedures such as diagnostic peritoneal lavage and computed tomography can significantly increase the rate of unnecessary operations leading to longer hospitalizations and operation-related morbidity. To reduce the failure rate of nonoperative management and nontherapeutic surgeries, modifications in current guidelines should be made.

Keywords: Wounds; Abdomen; Trauma

1. Background

Penetrating trauma to the abdomen can seriously threaten patient's life because of high risk of internal bleeding or peritonitis. Patients with clinical pictures suggestive of these complications should immediately undergo surgical management. However, laparoscopy or laparotomy reveals no significant finding in many cases of abdominal stab wounds, showing that they could have been managed nonoperatively (1, 2). Local wound exploration (LWE) was advocated by Markovchick in 1985 as the primary screening for the patients with anterior abdominal penetrating trauma. Authors suggested that negative results in LWE was indicative of intact peritoneal cavity and patient should be discharged from hospital after appropriate wound care without further investigations and therapeutic strategies (3). Until 1960, there was a dominant concept that all cases of abdominal penetrating trauma should be operated as soon as possible. Shaftan was the first to introduce a new approach called "selective conservatism" for management of these patients (2). Based on the new concept, patients are monitored by clinical examinations, wound exploration, and diagnostic procedures such as diagnostic peritoneal lavage (DPL), ultrasonography (USG), and computed tomography (CT) to minimize the number of cases who undergo unnecessary laparotomy (3-5). Since then, numerous studies have been conducted to

determine the criteria to decide which patients could be safely managed nonoperatively. In many trauma referral centers, management protocols and guidelines have been developed for this decision making. Success of these guidelines in management of patients with abdominal penetrating trauma helps minimize patients' hospital stay, complications, and cost of diagnostic and operative procedures (6-9). In our center (Rajaiee Trauma Center, Shiraz, Iran), we introduced and utilized a new guideline (Figure 1) since September 2012. According to our protocol, patients with unstable hemodynamics, peritonitis, and evisceration were immediately operated. The list of patients who are not conservatively managed in our center is brought in Box 1. Asymptomatic patients with stable vital signs are managed conservatively with serial abdominal physical exams (every two hours) and serial complete blood cell count (CBC) (every six hours) for 24 hours. Patients are kept in nil per os (NPO) condition for the first 24 hours. If there is no indication for operation during the first 24 hours, such as hemodynamic instability or development of signs of peritonitis, PO diet will be started and regularly advanced. In this protocol, we tried to minimize the utilization of CT scan and DPL diagnostic procedures as possible and monitor the patients with physical examinations and preferably with USG (10).

Box 1. Indication of Conversion From Conservative Management to Surgical Intervention

1. Unstable vital signs (systolic blood pressure < 90 mmHg, pulse rate > 100/min)
2. Penetrating injury due to gunshot
3. Thoracoabdominal, flank, and back injury
4. Peritonitis (rigidity, rebound tenderness)
5. Associated head or spinal cord injury

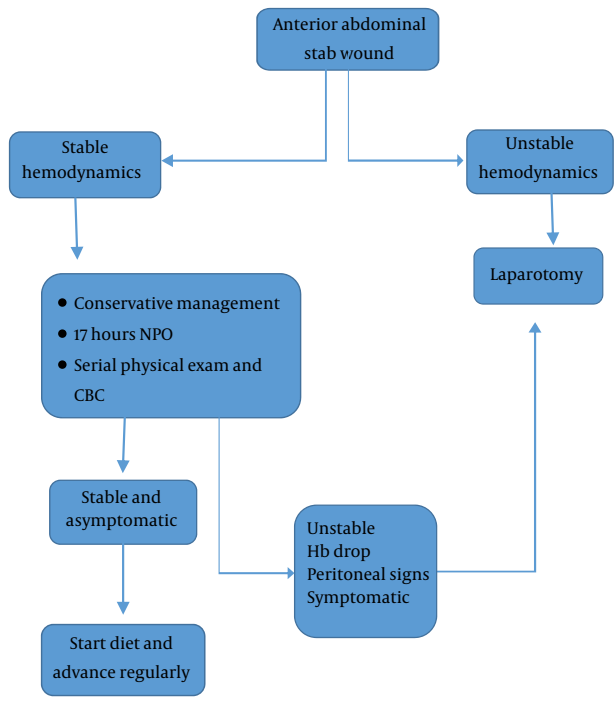


Figure 1. Nonoperative Management Guideline

2. Objectives

In the present study, we reported the outcome of this guideline during a 12-month period between September 2012 and September 2013.

3. Patients and Methods

In a prospective study between September 2012 and September 2013, among all patients who were referred to Rajaiee Trauma Center, those with anterior abdominal stab wound (AASW) who met the criteria for conservative management were enrolled. As discussed previously, patients who required immediate operation (hemodynamic instability, peritonitis, and evisceration) were excluded from the study. Demographic information such as age, sex, details of the accident, and location of stab wound were obtained and recorded in data gathering forms. Abdominal examination, vital signs, and CBC were checked and recorded regularly. Abdominal USG was performed in patients with signs and symptoms suggestive

of internal hemorrhage. CT scan was only performed in patients in which the laceration was located near a solid organ and solid organ injury could not be determined by physical examination. Patients who developed unstable vital signs or peritonitis were transferred to operation room (OR) for laparotomy. The interval between arrival and operation, feeding and discharge from hospital were measured. Descriptive analysis was used to report the failure rate of conservative management, rate of unnecessary laparotomy and essential laparotomies, and the length of hospitalization and duration of NPO condition. We also followed the patients after discharge from hospital to identify complicated patient. Since all patients were managed according to the general protocol of management of abdominal stab wounds of our center, and no alteration in medical procedures and treatment was made, no informed consent was required for this study. The present study was approved and supervised by board committee of medical ethics of Shiraz University of Medical Sciences and conformed to the ethical guidelines of the 1975 Declaration of Helsinki.

4. Results

During the 12-month study, 45 patients were enrolled, composed of 37 males and eight females with mean age of 34.4 years. In all patients, injury was caused by knife. Most frequent regions of the stab wound were consecutively left upper quadrant (37.8%), right upper quadrant (26.7%), and right lower quadrant (20%) of the abdomen. In three patients (6.6%), more than one region was stabbed. Of diagnostic procedures, USG was used in 71.1% of patients and CT scan in 15.6%. DPL was performed for none of the patients. In 27 patients (60%), laparotomy was performed due to hemoglobin drop, unstable vital signs, and signs of peritonitis. Peritonitis was the predominant cause of laparotomy in the study population accounting for 81.5% (22 patients) of those who underwent surgery. Unstable vital signs and hemoglobin drop was the cause of surgery in the rest of patients (18.5%). Among 27 patients who were transferred to OR for laparotomy, 14 (50.8%) had surgical findings suggestive of traumatic damage including solid organ and gastrointestinal injuries. Two patients had two spontaneous positive findings of surgery. Statistics for these findings are brought in Table 1. Among 22 patients who underwent laparotomy with impression of peritonitis, 11 patients had positive finding of operation. The most common findings were consecutively colon injury (six patients), liver damage (2 patients), mesocolon injury (2 patients), and pancreatic damage (1 patient). Positive operative findings were detected in three out of five patients who were transferred to OR due to hemoglobin drop or shock. Two of them had liver damage and one patient had both mesocolon and small bowel injury (Table 2). In the present study, the interval between arrival to emergency department and operation (in those who changed to operative management), oral diet, and

discharge were measured. The mean interval between arrival and operation was 6.35 hours (95% CI, 4-8.6). The interval between arrival and oral diet was 51.25 hours for the operative management group and 32.4 hours for the nonoperative management group. Mean hospitalization duration was 4.8 days for patients who underwent operation and 2.5 days for patients who were managed conservatively.

Table 1. Sites of Injury in Patients Who Underwent Laparotomy

| Site of Injury | No. (%) |
|----------------|----------|
| Liver | 4 (28.6) |
| Spleen | 1 (7.1) |
| Pancreas | 1 (7.1) |
| Small Bowel | 1 (7.1) |
| Colon | 6 (42.8) |
| Mesocolon | 3 (21.4) |

Table 2. Positive Operation Findings Regarding the Reason for Operation^a

| Reason For Surgery | Positive Surgical Finding |
|----------------------|---------------------------|
| Peritonitis (n = 22) | 11 (50) |
| Shock (n = 5) | 3 (60) |

^a Data are presented as No. (%).

5. Discussion

Non-operative management of abdominal penetrating trauma not only decreases the economic burden on health care system, but also reduces the complications and morbidity due to unnecessary laparotomies. Since 2011, Rajaiee Trauma Center, as the referral center of trauma in the south of Iran, has employed new guidelines for selective conservative management of patients with AASW. This management guideline focused in minimizing DPL as an invasive diagnostic procedure, and CT scan as an expensive and high-radiation procedure. Instead, we monitored patients by serial abdominal examinations, vital sign control, and CBC to detect complications such as shock and peritonitis, which would demand immediate surgical intervention. In this report, which included patients with AASW during a 12-month period, the outcome of mentioned protocol was evaluated. The rate of operative managements in this study was 66% with 45.8% negative laparotomies, indicating unnecessary and nontherapeutic surgery. The rate of successful nonoperative management of patients with AASW was estimated as 27% by Demetriades et al. in 2006; however, their study included all patients who presented with anterior abdominal injury including gunshots and those who were immediately operated (11). In another report by Navsaria et al. the rate of successful nonoperative management of AASW in 112 patients was 89.3%. The rate of negative

findings in laparotomy was 16.7%. In that study, patients who were assigned to be conservatively managed did not undergo USG examination, LWE, and DPL. The monitoring included serial abdominal physical examination and regular vital sign and hemoglobin measurement (12). The rate of delayed laparotomy indicative of unsuccessful conservative management and the percentage of negative laparotomies were high in our study in comparison to previous report. This variation might result from reduced utilization of CT scan and DPL. DPL has been regarded as a reliable diagnostic procedure for decision making in patients with AASW (13). In our center, performing of DPL is not preferred in a crowded emergency room and with agitated patients, as in the present study none of the patients underwent DPL. In the present study USG was the most assistive monitoring modality that has been reported low in sensitivity in evaluation of injuries of AASW (14). Due to high rate of laparotomies in the population that we selected for nonoperative management, we can conclude that we have to revise the protocol for more accurate determination of patients who are selected for nonoperative management. In addition, since the rate of negative laparotomies was higher in our study, we can state that more patients who were suspicious to have complications were rushed into the OR. Performing CT scan and DPL in patients who develop positive abdominal examinations, WBC rise, and Hb drop during conservative management, before making the decision for operating the patient, can reduce the rate of negative laparotomies in patients with AASW. In 2014, Peev et al. (15) reported that patients who had failed to improve under nonoperative management and had been operated with delay, did not experience prolonged hospital stay or complications in comparison to those who has been operated immediately. Considering the results of our study, that hospitalization duration was significantly shorter in patients with successful nonoperative management. Moreover, delayed surgery is safe and harmless; hence, we advocate selective nonoperative management with appropriate diagnostic procedures in patients who do not require immediate surgery after anterior abdominal penetrating trauma to minimize the rate of unnecessary surgery and its related morbidity. Based on the location of abdominal stab wound, we suggest performing DPL in patients with injury in the area of solid organs, which can reliably predict solid organ injuries.

Authors' Contributions

Study concept and design: Shahram Paydar; acquisition of data: Shahram Paydar, Vahid Shakoori, and Parsa Ravanfar; analysis and interpretation of data: Parsa Ravanfar and Shahram Paydar; drafting the manuscript: Parsa Ravanfar, Shahram Paydar, and Vahid Shakoori; critical revision of the manuscript for important intellectual content: Shahram Paydar and Parsa Ravanfar; statistical analysis: Parsa Ravanfar; administrative, technical, and

material support: Shahram Paydar; and study supervision: Shahram Paydar.

Funding/Support

This study was funded and supported by Trauma Research Center affiliated to Shiraz University of Medical Sciences.

References

1. Como JJ, Bokhari F, Chiu WC, Duane TM, Holevar MR, Tandoh MA, et al. Practice management guidelines for selective nonoperative management of penetrating abdominal trauma. *J Trauma*. 2010;**68**(3):721-33.
2. Biffl WL, Moore EE. Management guidelines for penetrating abdominal trauma. *Curr Opin Crit Care*. 2010;**16**(6):609-17.
3. Markovchick VJ, Moore EE, Moore J, Rosen P. Local wound exploration of anterior abdominal stab wounds. *J Emerg Med*. 1985;**2**(4):287-91.
4. Shaftan GW. Indications for operation in abdominal trauma. *Am J Surg*. 1960;**99**(5):657-64.
5. Thal ER. Evaluation of peritoneal lavage and local exploration in lower chest and abdominal stab wounds. *J Trauma*. 1977;**17**(8):642-8.
6. Biffl WL, Kaups KL, Pham TN, Rowell SE, Jurkovich GJ, Burlew CC, et al. Validating the Western Trauma Association algorithm for managing patients with anterior abdominal stab wounds: a Western Trauma Association multicenter trial. *J Trauma*. 2011;**71**(6):1494-502.
7. Omari A, Bani-Yaseen M, Khammash M, Qasaimeh G, Eqab F, Jaddou H. Patterns of anterior abdominal stab wounds and their management at Princess Basma teaching hospital, North of Jordan. *World J Surg*. 2013;**37**(5):1162-8.
8. Biffl WL, Kaups KL, Cothren CC, Brasel KJ, Dicker RA, Bullard MK, et al. Management of patients with anterior abdominal stab wounds: a Western Trauma Association multicenter trial. *J Trauma*. 2009;**66**(5):1294-301.
9. Casali M, Di Saverio S, Tugnoli G, Biscardi A, Villani S, Cancellieri F, et al. [Penetrating abdominal trauma: 20 years experience in a Western European Trauma Center]. *Ann Ital Chir*. 2008;**79**(6):399-407.
10. Paydar S, Salahi R, Izadifard F, Jaafari Z, Abbasi HR, Eshraghian A, et al. Comparison of conservative management and laparotomy in the management of stable patients with abdominal stab wound. *Am J Emerg Med*. 2012;**30**(7):1146-51.
11. Demetriades D, Velmahos G. Technology-driven triage of abdominal trauma: the emerging era of nonoperative management. *Annu Rev Med*. 2003;**54**:1-15.
12. Navsaria PH, Berli JU, Edu S, Nicol AJ. Non-operative management of abdominal stab wounds—an analysis of 186 patients. *S Afr J Surg*. 2007;**45**(4):128-30.
13. Gonzalez RP, Turk B, Falimirski ME, Holevar MR. Abdominal stab wounds: diagnostic peritoneal lavage criteria for emergency room discharge. *J Trauma*. 2001;**51**(5):939-43.
14. Udobi KF, Rodriguez A, Chiu WC, Scalea TM. Role of ultrasonography in penetrating abdominal trauma: a prospective clinical study. *J Trauma*. 2001;**50**(3):475-9.
15. Peev MP, Chang Y, King DR, Yeh DD, Kaafarani H, Fagenholz PJ, et al. Delayed Laparotomy After Selective Non-operative Management of Penetrating Abdominal Injuries. *World J Surg*. 2014.