

## Foramen of Winslow Hernia: A Case Report and Literature Review

Chin Li Tee<sup>1,\*</sup>; Bree Stephensen<sup>1</sup>; Thushara Dissanayake<sup>1</sup>; David A. Grieve<sup>1</sup>

<sup>1</sup>Department of Surgery, Nambour Hospital, Nambour, Australia

\*Corresponding author: Chin Li Tee, Department of Surgery, Nambour Hospital, Nambour, Australia. Tel: +61-75470 6600, E-mail: tee\_jimmy@hotmail.com

Received: November 27, 2014; Revised: December 6, 2014; Accepted: December 9, 2014

**Introduction:** Foramen of Winslow hernia is a rare occurrence, accounting for only 8% of all internal hernias and 0.08% of all hernias. It presents a diagnostic challenge with subtle clinical and radio-logical features. A delay in treatment is responsible for high mortality rates of around 36-49%.

**Case Presentation:** Here we describe a case of a 31-year-old man who presented with acute epigastric pain. Extensive diagnostic work-up suggested foramen of Winslow hernia. At laparotomy, the herniated small bowel was viable and reduction was achieved with gentle traction.

**Conclusions:** Successful management of foramen of Winslow hernia requires prompt diagnosis and surgical treatment.

**Keywords:** Small Intestine; Hernia; Peritoneal Cavity

### 1. Introduction

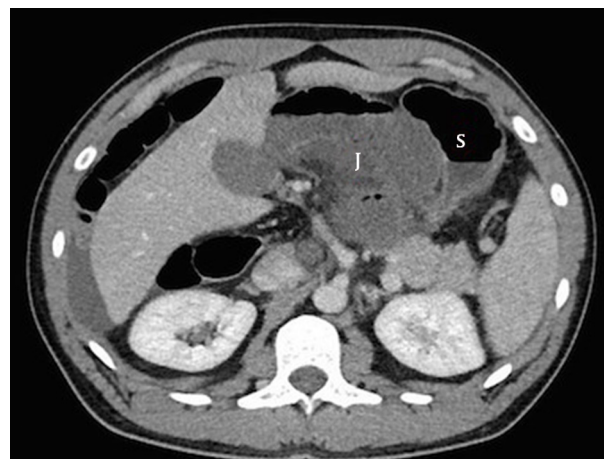
Internal hernia is a protrusion of a viscus into a natural orifice of the abdominal cavity. Herniation through the foramen of Winslow is rare, accounting for only 8% of internal hernias and 0.08% of all abdominal hernias (1). It most frequently involves the small bowel (63%), followed by the caecum and right colon (30%) and the transverse colon (7%). Cases of herniation of gall - bladder, omentum, and small bowel diverticulum have also been reported (2).

### 2. Case Presentation

A 31-year-old man presented to emergency department with sudden onset of epigastric pain. The pain was colicky in nature with no radiation, and it was relieved by truncal flexion. There was associated nausea and vomiting. He had no past medical or surgical history. On examination, vital signs were within normal limits. Abdominal examination revealed a soft abdomen with marked tenderness in the epigastrium and right upper quadrant. Full blood count, electrolytes, renal function, liver function and lipase were all normal except for a mildly elevated white cell count of  $12.9 \times 10^9/L$ . CT scan of the abdomen revealed herniation of small bowel into the lesser sac causing a closed - loop obstruction (Figures 1 and 2). The patient underwent an urgent laparotomy, which confirmed a foramen of Winslow hernia.

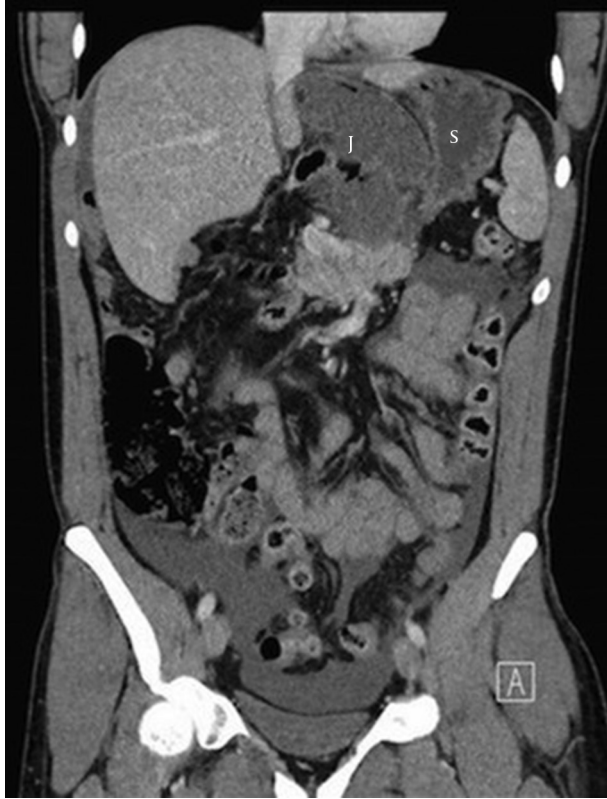It contained 25 - 30 cm of dusky but viable jejunum. The hernia was reduced by gentle traction. Post - operatively, the patient made an unremarkable recovery and was discharged after 4 days. There is no evidence of recurrence to date.

Figure 1. Jejunum Lying in the Lesser Sac (Axial View)



J: Jejunum, S: Stomach

**Figure 2.** Jejunum Seen Herniating Through the Foramen of Winslow to the Lesser Sac, Displacing the Stomach Laterally (Coronal View)



J: Jejunum, S: Stomach

### 3. Discussion

The first case of Foramen of Winslow hernia was reported by Square in 1886 (3). Foramen of Winslow hernias are a rare subgroup of internal hernias. Several predisposing factors have been postulated by Moynihan: a) long and mobile mesentery of the bowel which affords the bowel excess mobility, b) excessively large Foramen of Winslow (admits more than one finger), c) absence of fusion of ascending colon to posterior abdominal wall (4, 5). Other predisposing factors stated in the literature include elongated right hepatic lobe, which could be directing the mobile intestinal loop into the foramen, and incomplete intestinal rotations or malrotations (6, 7).

The most common complication of this hernia is small bowel obstruction which may lead to strangulation (8). Others include gastric outlet obstruction due to extrinsic compression of pylorus, intestinal perforation, and the formation of a fibrous constriction ring involving the herniated segment after reduction. Mild obstructive jaundice has been noted in several cases, due to compression of the common bile duct (2, 9). The following clinical features should suggest an obstructed internal hernia through the foramen of Winslow: a tympanic epigastric mass; sudden onset of severe epigastric pain eased by

sitting or truncal flexion; and no history of previous abdominal surgery (9). It has been postulated that flexing the trunk opens the Foramen of Winslow (4).

There are a number of radiological features which have been described in the literature: a) a circum-scribed collection of gas medial to the lesser curvature, displacing the stomach laterally and anteriorly, may be present, b) absence of right colon in the right gutter, c) presence of mesentery between the portal vein and the inferior vena cava, and d) presence of terminal ileum and ascending colon displaced superiorly in the sub-hepatic space (4, 10). A CT scan can improve the specificity of the diagnosis. Though it has been suggested that the hernia is only diagnosed pre-operatively in less than 10% of cases (11), we suspect that pre-operative diagnosis would well exceed 10% with the widespread use of fast and high quality CT imaging, as in our case.

Urgent operative management is indicated and it frequently involves reduction through the defect with simple traction (1-4). Should reduction not be successful, an option is to enter the lesser sac by making an incision in the gastrocolic ligament to assist in delivering the incarcerated segment of bowel (2, 12). Successful laparoscopic management of Foramen of Winslow hernia has been reported (1, 12). Bowel resection is dependent on the viability of the bowel after its reduction.

There is debate as to the appropriate management to prevent recurrence, including foramen closure, or right hemicolectomy or caecal fixation in the case of herniation of caecum and ascending colon (2, 4). There is very little evidence for recurrent herniation. Moreover, closure of foramen might pose a risk to the portal vein, inferior vena cava and biliary ducts, and may also result in portal vein thrombosis and fibrosis (10). In our case, we elected not to close the foramen of Winslow.

Foramen of Winslow hernia is a rare condition which carries a high mortality rate from misdiagnosis and treatment delay. It needs to be recognised and managed promptly to avoid potential life-threatening complications.

### Acknowledgements

The authors would like to acknowledge Nambour Hospital for the support and resources given in the publication of this paper.

### Authors' Contributions

Chin Li Tee and Bree Stephensen: Writing of the case report and literature review, Thushara Dissanayake and David A. Grieve: Editing of the articles, study supervision.

### References

1. Van Daele E, Poortmans M, Vierendeels T, Potvlieghe P, Rots W. Herniation through the foramen of Winslow: a laparoscopic approach. *Hernia*. 2011;**15**(4):447-9.
2. Koh CE, Woods SDS, Usatoff V. Foramen of Winslow hernia. *Surg Prac*. 2007;**11**(2):81-3.

3. Square JE. A Case of Strangulated Internal Hernia into the Foramen of Winslow. *Br Med J*. 1886;**1**(1329):1163.
4. Powell-Brett SF, Royle JT, Stone T, Clarke RG. Caecum herniation through the Foramen of Winslow. *J Surg Case Rep*. 2012;**2012**(12).
5. Puig CA, Lillegard JB, Fisher JE, Schiller HJ. Hernia of cecum and ascending colon through the foramen of Winslow. *Int J Surg Case Rep*. 2013;**4**(10):879-81.
6. Martin LC, Merkle EM, Thompson WM. Review of internal hernias: radiographic and clinical findings. *AJR Am J Roentgenol*. 2006;**186**(3):703-17.
7. Duarte GG, Fontes B, Poggetti RS, Loreto MR, Motta P, Biroolini D. Strangulated internal hernia through the lesser omentum with intestinal necrosis: a case report. *Sao Paulo Med J*. 2002;**120**(3):84-6.
8. Pegg SP. Hernia of the foramen of Winslow: a case report. *Aust N Z J Surg*. 1970;**40**(2):170-2.
9. Heathwood CM, Strong R, Borton MM, Reasbeck PG. Foramen of Winslow hernia. *Aust N Z J Surg*. 1987;**57**(11):875-7.
10. Osvaldt AB, Mossmann DF, Bersch VP, Rohde L. Intestinal obstruction caused by a foramen of Winslow hernia. *Am J Surg*. 2008;**196**(2):242-4.
11. Ryan J, Jin S, Frank J, Jacobs R. Internal herniation of the caecum through the foramen of Winslow. *ANZ J Surg*. 2014;**84**(1-2):95-6.
12. Sved PD, Peck N, Smith RC. Laparoscopic diagnosis and management of foramen of Winslow hernia - case report. *Minim Invasiv Ther*. 1996;**5**(6):575-6.