

Solitary Rectal Ulcer: A Literature Review

Bitá Geramizadeh,^{1,*} Mohammad Baghernezhad,¹ and Arezoo Jahanshani Afshar¹

¹Pathology Department, Transplant Research Center, Shiraz University of Medical Sciences, Shiraz, IR Iran

*Corresponding author: Bitá Geramizadeh, Pathology Department, Transplant Research Center, Shiraz University of Medical Sciences, Shiraz, IR Iran. Tel/Fax: +98-7136473238, E-mail: geramib@sums.ac.ir

Received 2015 September 30; Revised 2015 November 7; Accepted 2015 November 7.

Abstract

Context: Solitary rectal ulcer (SRU) is a disease with many challenging issues. There are several controversies about the basic pathophysiology of this disease. Despite its name, "solitary rectal ulcer", more than a quarter of patients do not show any ulcer in colonoscopy. Instead, many patients show multiple polypoid lesions. Some previous reports have suggested calling this disease "rectal mucosal prolapse" instead of SRU, however, most of the patients do not have mucosal prolapse. In addition, colonoscopic findings can be very similar to cancer and inflammatory bowel disease, so without histologic evaluation, accurate diagnosis is not always possible. In patients with SRU, sometimes the rectal mucosa is so fibrotic that mucosal biopsy is inadequate, and even a pathologist cannot diagnose the characteristic histologic findings. There are various therapeutic approaches for the treatment of SRU, both surgical and nonsurgical, all of which are not optimal, and recurrence rates are still high with many patients experiencing complications even after surgery, resection and rectopexy.

Evidence Acquisition: Although this disease is not uncommon in Iran, there are very few studies from Iran, therefore, in this review we will describe our experience with patients with SRU in affiliated hospitals of Shiraz University of Medical Sciences. We will also review previously published articles about SRU that are indexed in PubMed and Google scholar, emphasizing the challenging issues.

Results: SRU is not an uncommon disease in Iran, however the number of published articles about it, is very low. Multicentric studies are necessary to find out the definite reason of this issue.

Conclusions: There are still many conflicting controversies about the etiology, pathogenesis, diagnosis and also treatment of SRU, which need further investigation and longer follow up of the patient in each therapeutic approach to be better understood.

Keywords: Solitary Rectal Ulcer, Iran, Review

1. Context

1.1. Historical Aspect

Solitary rectal ulcer (SRU) has been reported as an uncommon and benign condition, which was introduced more than a century ago, in 1829, by Cruveihier as four cases of unusual rectal ulcers (1). It remained unknown until 1930, when Lloyd-Davis described it as a solitary ulcer of the rectum. It was widely recognized in 1969 via an article published by Madigan and Morson (2) in which they described 68 cases with this disorder, and the disease was fully described by Rutter and Riddell in 1975 in respect to its pathogenesis (3).

Now, after more than 40 years, more than 200 articles have been published, many of which are single case reports describing isolated cases of SRU. However, only four articles have been published that describe the experience of Iranian scientists with this disease (4-7).

2. Evidence Acquisition

According to our experience, as the largest gastrointestinal center in the South of Iran, this disease is not

uncommon in Iran, and many patients of all different ages, especially the younger population including children, are struggling with SRU. In this review, we will also describe the previous experiences of different countries, as well as our experience with SRU, in colon biopsies of patients of different ages that have undergone colonoscopy in affiliated hospitals of Shiraz University of Medical Sciences.

3. Results

3.1. Prevalence and Demographic Findings

The estimated annual prevalence of SRU has been reported as one in 100,000 persons (8). In our center, in the five years studied, among 3,034 colon biopsies, 135 (4.45%) cases have been reported as SRU by GI pathologists. Patients with SRU were between 1 and 81 years of age (28.25 ± 19.5). Of these, sixty patients were female and 75 were male.

Table 1 shows the demographic characteristics of patients in different countries that have been studied in the large centers for treatment of gastrointestinal diseases (8-12).

Table 1. Reported Demographic Characteristics of Previous Articles

	Years of Study	Number of Patients	Age ^a	Female	Male
Europe (France) (8)	1997 – 2002	25	37.2 ± 15.7	4	21
USA (9)	1997 – 2009	12	15.6 ± 9.8	0	12
Pakistan (10)	1990 – 2011	116	37.4 ± 16	NR	NR
Saudi Arabia (11)	2006 – 2013	12	43.9 ^b	6	6
Kuwait (12)	2002 – 2007	13	15 – 85 ^c	5	8
Current Study (Iran)	2005 – 2010	135	28.25 ± 19.5	60	75

^aData are presented as mean ± SD.

^bData presented as mean.

^cData presented as range.

As the table shows, males have been affected more than females, although the difference is not significant. The age range of the patients is very similar in different geographic locations; the most common age of presentation has been between 15.5 and 43 years old. This disease is extremely rare after 70, and in elderly patients accompanying diseases, such as rectal cancer, should be investigated (8, 10, 13).

Table 1 also shows that the number of SRU patients from our department, in the five years, is not low, and in comparison to other centers SRU seems to be more prevalent in Iran. It is also worthy to note that one of the largest series of studies of children with SRU has been published from our center (5).

3. 2. Pathophysiology

The exact underlying cause of SRU is not fully understood, however, there are several theories regarding the pathophysiology of the disease (6). All of the proposed theories can be categorized as follows:

Rectal hypersensitivity leading to persistent desire to defecate and sensation of incomplete evacuation (14).

Inappropriate and paradoxical contraction of the puborectalis muscle, which causes obstruction during defecation and compression of the anterior wall of the rectum with prolapse and intussusceptions of rectal mucosa (15).

Venous congestion of the rectal mucosa and ischemia of the rectal mucosa causing ulceration (16).

Trauma of the rectal mucosa, secondary to descent of the perineum due to a squatting position for defecation (17).

Rectal mucosal trauma can be secondary to rectal digitation (18).

Excessive straining for defecation causes anterior rectal mucosa to move downwards against the underlying pelvic floor, causing trauma and focal ischemia of rectal mucosa (19-21).

3. 3. Clinical Manifestation

The most common presenting symptom in almost all of the reported cases (82% – 100%) in all age groups has been fresh rectal bleeding (20). Rectal bleeding varies from a small amount of fresh blood to severe hemorrhaging

that requires blood transfusion. Massive rectal bleeding requiring emergency endoscopy to find the underlying cause has also rarely been reported (7, 22, 23). One report from Italy has described death due to a missed case of SRU, which was diagnosed in autopsy of a 57-year-old man after unknown cause of death (24).

Mucus passing (17% – 64%) and hard stool (26% – 78%), as well as intermittent episodes of diarrhea and constipation, have also been among the frequent symptoms (19). Many patients have the complaint of pelvic discomfort and pain, the sensation of incomplete evacuation, the intense urge of defecation and frequent visits to the toilet (more than one per hour) with little or no stool on most occasions, requiring digital application to evacuate stool (7% – 33%) (18). Many patients also have a history of frequent use of laxatives (17).

The less common symptoms have been fecal and/or urinary incontinence (16). Lower abdominal pain has also been reported, although most commonly has been accompanied with perineal and pelvic discomfort and pain (25). On the other hand, there has not been any report of weight loss or fever in uncomplicated SRU (18).

It should be mentioned that the above symptoms are more difficult to diagnose and distinguish during childhood, mostly because the symptoms are more variable and more than 20% of pediatric patients are asymptomatic (26-30).

3. 4. Colonoscopic Findings

The most common endoscopic finding in SRU is ulceration, which is present in more than 90% of the cases (8). Typically, the ulcer is shallow and surrounded by hyperemic mucosa (10). The ulcer can be solitary or multiple, circumferential and is usually located in the anterior or anterolateral wall of the rectum, 3 – 10 cm from the anal verge (15). Ulcers may range from 0.5 to 4 cm in diameter but are usually 1 to 1.5 cm in diameter (26). Rarely, ulcers can cause massive bleeding from a visible vessel under endoscopy (22, 23, 31, 32). There are also reports of GI bleeding from a rectal ulcer, with histologic findings similar to gastric heterotopia, which is very rare in the rectum (33). Also rare, SRU has been reported in endoscopically normal ap-

pearing or mildly hyperemic erythematous mucosa (10). In some of the cases, telangiectatic spots have also been reported, in addition to ulcer or hyperemic mucosa (15).

In contrast to its name, SRU can present without any ulcer, and in about 10% – 25% of cases it presents as nodular and polypoid mucosa (15). In some cases, these polyps can be multiple, as polypoid masses (33, 34). It seems that the occurrence of SRU is part of the evolution from polypoid to ulcerative lesions in patients with rectal prolapse (19). According to previous case reports and case series, ulcers and polyps have been the most common endoscopic findings in more than 90% of patients with SRU (34-38).

Some of the endoscopic findings in this disease can be completely nonspecific, such as the presence of thickened mucosa (12) and stricture, which can be very similar to cancer (19, 39-44). The endoscopic findings of SRU can mostly be similar to inflammatory bowel diseases and rectal carcinoma, which necessitate concomitant biopsy for definitive diagnosis (44).

3.5. Histologic Findings

The best and most accurate diagnostic method in SRU is rectal biopsy with histologic findings of SRU. This method is necessary to exclude other diseases, especially cancer (6) (Figure 1).

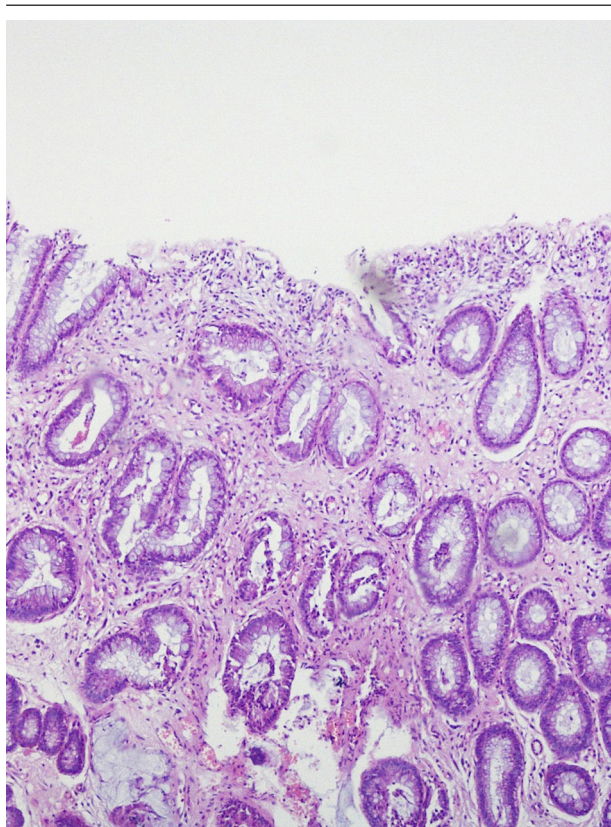


Figure 1. Sections from a Case of Typical SRU With Characteristic Findings of Dense Collagen in Lamina Propria, With Vertical Muscle Between the Glands and no Chronic Inflammation

The major histological features of SRU are as follows:

Fibromuscular obliteration of the lamina propria.

Hypertrophied muscularis mucosa.

Extension of muscle fibers upwards between the crypts.

Diffuse collagen deposition in the lamina propria and abnormal smooth muscle fiber.

Mild glandular crypt abnormalities (1).

The minor histologic features of SRU are as follows:

Surface erosion, which is covered by mucus, pus and detached epithelial cells and may show reactive hyperplasia (3, 4).

In more than 90% of the cases, ulceration with infiltration of acute inflammatory cells can be seen, however, chronic inflammatory cell infiltration is very rare and scarce. This finding, plus collagen deposition in the lamina propria, are two features that are very important to exclude inflammatory bowel disease. In endoscopy, these two lesions can be very similar and the most helpful and accurate method of diagnosis for differentiation (ulcerative colitis and Crohn's disease vs. SRU) is colon biopsy and histologic findings (45-47).

Another very important consideration in histologic findings of SRU is the rare association of SRU with malignancy, especially in patients older than 40 years of age, when SRU is much less common. There are reports of rectal mass, in which in the first biopsy only the histopathologic changes of SRU were present, and carcinoma was evident in subsequent specimens after one to five repeat biopsies (with delay in diagnosis from one week to 18 months in six patients) (47).

Another diagnostic challenge in histopathologic diagnosis of SRU is the presence of reactive atypia in the surface epithelial cells, because of ulceration and regenerative atypia, which should be differentiated from malignancy and dysplasia (48).

It seems that according to histopathology, the two most important differential diagnoses are the same as colonoscopy, i.e. inflammatory bowel disease and malignancy, however, an expert GI pathologist should be consulted to prevent an erroneous diagnosis (49, 50).

3.6. Other Diagnostic Methods

An accurate diagnosis of SRU is most commonly made based on a combination of symptoms, endoscopic findings and histological appearances. Imaging studies play a limited role in the diagnosis of SRU, but they can help to define the underlying disorder (51, 52).

Magnetic resonance imaging (MRI), transrectal and endoanal sonography, defecating proctography and barium enema are the three most commonly reported methods for imaging studies in the diagnosis of SRU (53).

Typical reported features on transrectal and endoanal ultrasonography are poor relaxation of the puborectalis muscle during straining, thickened muscularis propria and the absence of distinction between the mucosa and the muscularis propria, and marked thickening of the internal and external sphincter (53). Sonographic findings

of a thick internal anal sphincter are highly predictive for high-grade rectal intussusception in patients with solitary rectal ulcer syndrome (38).

Another reported method is defecation proctography that shows internal rectal prolapse, external rectal prolapse and delayed or incomplete emptying (54). Defecography has also been reported to evaluate the puborectalis muscle's inappropriate contraction, which is useful mostly in patients with no response to primary treatments (55). Barium enema in SRU shows thickening of the rectal folds, stricture formation, polypoid lesions and ulceration, which can be very similar to malignant lesions (56).

MRI has very rarely been reported as a diagnostic tool in SRU; however, it has been reported in a few cases endoscopically suspected of cancer, which have undergone MRI for staging (51-53). In these very few cases, MRI findings have been non-specific and indistinguishable from a malignant process. However, in a young patient with compatible clinical and endoscopic findings of SRU, presence of thickened rectal mucosa in anterior and anterolateral location could be suggestive of SRU (53).

3. 7. Treatment

SRU is difficult to treat because the pathogenesis is not clearly understood, and it is also associated with various pelvic floor disorders (57). Therefore, the choice of treatment depends on the severity of the disease and whether or not it is associated with pelvic floor disorders (58). The first line of treatment in most cases is nonsurgical. Surgery is reserved for patients unresponsive to conservative therapy (59). Conservative treatments including laxatives, fiber supplementation and attempted reduction of straining are reported as the first line of treatment (60).

A behavioral approach seems to have therapeutic benefit for some patients with SRU. Especially in patients with a history of chronic excessive straining, this can help to direct treatment towards retraining toileting behavior (61). Some studies have reported that biofeedback therapy involves more than just retraining pelvic floor coordination. This method also helps patients to know the necessary posture for defecation and use of the abdominal muscles, and to decrease the number of visits to the toilet, time spent in the toilet, digitation and laxative use (62, 63). The term "biofeedback" relates to a complex combination of behavioral changes, attention to the defecatory process and possibly other psychological effects (64). The real problem with this method is the low number of patients who can stick with this kind of treatment, which causes treatment failure (65).

Medical therapy for SRU is the second line of treatment. In some case reports, topical medical therapy, such as sucralfate, has been used with an unequivocal response and has not been definitely useful (66, 67). In very few cases, medical therapies such as sulfasalazine have been used with acceptable results but high recurrence (68). Recently, a few studies have used botulinum toxin (Botox) with no

completely acceptable results reported (69). Argon plasma coagulation (APC) is used in a wide range of gastrointestinal bleeding cases to stop bleeding (70). It has been reported in the treatment of SRU, either alone or accompanied by surgery and biofeedback. Many patients who have undergone APC had a reduction in size and depth of ulcers compared to their pretreatment appearance (71, 72). The widely accepted indication for surgical treatment is treatment failure (73). There are several methods of surgical procedures, some of which are open surgeries and some which are performed by laparoscopy (74).

According to the previous studies, stopping even occult prolapse may lead to rapid healing of the solitary rectal ulcer (75, 76). One of the most popular surgeries to treat rectal prolapse, is rectopexy (77). Laparoscopic rectopexy with and without mesh, according to previous reports has been shown to provide good results in patients with rectal prolapse (78-84). However, it seems that postoperative complications of rectopexy are not low, and preoperative behavioral disorder and constipation increases the risk of postoperative problems (85, 86). Prolonged preoperative evacuation time and defecatory disorder may predict a poor symptomatic outcome (87).

4. Conclusions

Much about the etiology, pathogenesis, diagnosis and also treatment of SRU is still not well understood. More studies are necessary to find the best method of treatment with less complication and a low recurrence rate.

Footnote

Authors' Contribution: Bita Geramizadeh: Running the project and writing the paper; Mohammad Baghernezhad: Collecting and evaluating the published material; Arezoo jahanshai Afshar: Collecting the patient data.

References

- Zhu QC, Shen RR, Qin HL, Wang Y. Solitary rectal ulcer syndrome: clinical features, pathophysiology, diagnosis and treatment strategies. *World J Gastroenterol.* 2014;**20**(3):738-44. doi: 10.3748/wjg.v20.i3.738. [PubMed: 24574747]
- Madigan MR, Morson BC. Solitary ulcer of the rectum. *Gut.* 1969;**10**(11):871-81. [PubMed: 5358578]
- Rutter KR, Riddell RH. The solitary ulcer syndrome of the rectum. *Clin Gastroenterol.* 1975;**4**(3):505-30. [PubMed: 1183059]
- Kargar S, Salmanroughani H, Binesh F, Taghipoor S, Kargar S. Laparoscopic rectopexy in solitary rectal ulcer. *Acta Med Iran.* 2011;**49**(12):810-3. [PubMed: 22174170]
- Dehghani SM, Haghighat M, Imanieh MH, Geramizadeh B. Solitary rectal ulcer syndrome in children: a prospective study of cases from southern Iran. *Eur J Gastroenterol Hepatol.* 2008;**20**(2):93-5. doi: 10.1097/MEG.0b013e3282fcb66. [PubMed: 18188027]
- Dehghani SM, Malekpour A, Haghighat M. Solitary rectal ulcer syndrome in children: a literature review. *World J Gastroenterol.* 2012;**18**(45):6541-5. doi: 10.3748/wjg.v18.i45.6541. [PubMed: 23236227]
- Yazdanpanah K, Shavakhi A, Sanei MH, Pezeshki AH, Sarrami AH. An unusual endoscopic presentation of solitary rectal ulcer syndrome. *Indian J Gastroenterol.* 2013;**32**(1):58-9. doi: 10.1007/s12664-012-0184-2. [PubMed: 22585569]

8. Morio O, Meurette G, Desfourneaux V, D'Halluin PN, Bretagne JF, Siproudhis L. Anorectal physiology in solitary ulcer syndrome: a case-matched series. *Dis Colon Rectum*. 2005;**48**(10):1917-22. doi: 10.1007/s10350-005-0105-x. [PubMed:16132482]
9. Perito ER, Mileti E, Dalal DH, Cho SJ, Ferrell LD, McCracken M, et al. Solitary rectal ulcer syndrome in children and adolescents. *J Pediatr Gastroenterol Nutr*. 2012;**54**(2):266-70. doi: 10.1097/MPG.0b013e318240bba5. [PubMed: 22094902]
10. Abid S, Khawaja A, Bhimani SA, Ahmad Z, Hamid S, Jafri W. The clinical, endoscopic and histological spectrum of the solitary rectal ulcer syndrome: a single-center experience of 116 cases. *BMC Gastroenterol*. 2012;**12**:72. doi: 10.1186/1471-230X-12-72. [PubMed: 22697798]
11. Albasri AM. Histopathological profile of benign colorectal diseases in Al-Madinah region of Saudi Arabia. *Asian Pac J Cancer Prev*. 2014;**15**(18):7673-7. [PubMed: 25292045]
12. Al-Brahim N, Al-Awadhi N, Al-Enezi S, Alsurayei S, Ahmad M. Solitary rectal ulcer syndrome: a clinicopathological study of 13 cases. *Saudi J Gastroenterol*. 2009;**15**(3):188-92. doi: 10.4103/1319-3767.54749. [PubMed:19636181]
13. Choi HJ, Shin EJ, Hwang YH, Weiss EG, Noguera JJ, Wexner SD. Clinical presentation and surgical outcome in patients with solitary rectal ulcer syndrome. *Surg Innov*. 2005;**12**(4):307-13. [PubMed:16424950]
14. El-Khayat HA, El-Hodhod MA, Abd El-Basset FZ, Tomoum HY, El-Safory HA, Hamdy AM. Rectal bleeding in Egyptian children. *Ann Trop Paediatr*. 2006;**26**(4):337-44. doi: 10.1179/146532806X152863. [PubMed:17132299]
15. Ortega AE, Klipfel N, Kelso R, Petrone P, Roman I, Diaz A, et al. Changing concepts in the pathogenesis, evaluation, and management of solitary rectal ulcer syndrome. *Am Surg*. 2008;**74**(10):967-72. [PubMed:18942624]
16. Keshtgar AS. Solitary rectal ulcer syndrome in children. *Eur J Gastroenterol Hepatol*. 2008;**20**(2):89-92. doi: 10.1097/MEG.0b013e3282f402c1. [PubMed:18188026]
17. Ertem D, Acar Y, Karaa EK, Pehlivanoglu E. A rare and often unrecognized cause of hematochezia and tenesmus in childhood: solitary rectal ulcer syndrome. *Pediatrics*. 2002;**110**(6):e79. [PubMed:12456946]
18. Martin de Carpi J, Vilar P, Varea V. Solitary rectal ulcer syndrome in childhood: a rare, benign, and probably misdiagnosed cause of rectal bleeding. Report of three cases. *Dis Colon Rectum*. 2007;**50**(4):534-9. doi: 10.1007/s10350-006-0720-1. [PubMed:17080282]
19. Gopal DV, Young C, Katon RM. Solitary rectal ulcer syndrome presenting with rectal prolapse, severe mucorrhea and eroded polypoid hyperplasia: case report and review of the literature. *Can J Gastroenterol*. 2001;**15**(7):479-83. [PubMed:11493953]
20. Lam TC, Lubowski DZ, King DW. Solitary rectal ulcer syndrome. *Baillieres Clin Gastroenterol*. 1992;**6**(1):129-43. [PubMed:1586765]
21. Amaechi I, Papagrigroriadis S, Hizbullah S, Ryan SM. Solitary rectal ulcer syndrome mimicking rectal neoplasm on MRI. *Br J Radiol*. 2010;**83**(995):e221-4. doi: 10.1259/bjr/24752209. [PubMed:20965892]
22. Urganc N, Kalyoncu D, Usta M, Eken KG. A rare cause of severe rectal bleeding: solitary rectal ulcer syndrome. *Pediatr Emerg Care*. 2014;**30**(10):736-8. doi: 10.1097/PEC.0000000000000239. [PubMed: 25275355]
23. Kato K, Nagase A, Iwasaki Y, Taniguchi M. Massive bleeding from visible vessels within a solitary rectal ulcer. *Surgery*. 2014;**155**(5):956-7. doi: 10.1016/j.surg.2012.12.006. [PubMed: 23499015]
24. Fedakar R, Akan O, Eren B, Turkmen N, Cetin S. Death Due to Perforation of Solitary Rectal Ulcer: Case Report. *Soud Lek*. 2014;**59**(2):14-6. [PubMed: 24754369]
25. Kiristioğlu I, Balkan E, Kilic N, Dogruyol H. Solitary rectal ulcer syndrome in children. *Turk J Pediatr*. 2000;**42**(1):56-60. [PubMed:10731872]
26. Sharara AI, Azar C, Amr SS, Haddad M, Eloubeidi MA. Solitary rectal ulcer syndrome: endoscopic spectrum and review of the literature. *Gastrointest Endosc*. 2005;**62**(5):755-62. doi: 10.1016/j.gie.2005.07.016. [PubMed:16246692]
27. Blackburn C, McDermott M, Bourke B. Clinical presentation of and outcome for solitary rectal ulcer syndrome in children. *J Pediatr Gastroenterol Nutr*. 2012;**54**(2):263-5. doi: 10.1097/MPG.0b013e31823014c0. [PubMed: 22266488]
28. Ertem D. An overlooked entity in children with rectal bleeding: solitary rectal ulcer. *J Pediatr Gastroenterol Nutr*. 2012;**54**(2):169-70. doi: 10.1097/MPG.0b013e318240bbc2. [PubMed: 22094903]
29. Temiz A, Tander B, Temiz M, Baris S, Ariturk E. A rare cause of chronic rectal bleeding in children; solitary rectal ulcer: case report. *Ulus Travma Acil Cerrahi Derg*. 2011;**17**(2):173-6. [PubMed: 21644097]
30. K CS, Sharma S, Basnet B, Mishra AK. Solitary rectal ulcer syndrome: uncommon cause of rectal bleeding in children. *JNMA J Nepal Med Assoc*. 2008;**47**(172):238-40. [PubMed:19079404]
31. Yagnik VD. Massive rectal bleeding: rare presentation of circumferential solitary rectal ulcer syndrome. *Saudi J Gastroenterol*. 2011;**17**(4):298. doi: 10.4103/1319-3767.82592. [PubMed:21727744]
32. Binderow SR, Mayer R, Freed JS. Massive hemorrhage from solitary rectal ulcer: toward a definitive treatment. *Mt Sinai J Med*. 1995;**62**(4):308-11. [PubMed: 7565856]
33. Al-Hussaini A, Lone K, Al-Sofyani M, El Bagir A. Gastric heterotopia of rectum in a child: a mimicker of solitary rectal ulcer syndrome. *Ann Saudi Med*. 2014;**34**(3):245-9. doi: 10.5144/0256-4947.2014.245. [PubMed:25266186]
34. Brosens LA, Montgomery EA, Bhagavan BS, Offerhaus GJ, Giardiello FM. Mucosal prolapse syndrome presenting as rectal polyposis. *J Clin Pathol*. 2009;**62**(11):1034-6. doi: 10.1136/jcp.2009.067801. [PubMed:19861563]
35. Suresh N, Ganesh R, Sathiyasekaran M. Solitary rectal ulcer syndrome: a case series. *Indian Pediatr*. 2010;**47**(12):1059-61. [PubMed: 20453265]
36. Chiang JM, Changchien CR, Chen JR. Solitary rectal ulcer syndrome: an endoscopic and histological presentation and literature review. *Int J Colorectal Dis*. 2006;**21**(4):348-56. doi: 10.1007/s00384-005-0020-6. [PubMed:16133006]
37. Gabra HO, Roberts JP, Variend S, Shawis RN. Solitary rectal ulcer syndrome in children. A report of three cases. *Eur J Pediatr Surg*. 2005;**15**(3):213-6. doi: 10.1055/s-2004-821180. [PubMed:15999319]
38. Cola B, Cuicchi D, Dalla Via B, Lecce F. Endosonographic pattern of solitary polypoid rectal ulcer. *Tech Coloproctol*. 2005;**9**(1):71-2. doi: 10.1007/s10151-005-0199-0. [PubMed:15868506]
39. Baskonus I, Maralcan G, Gokalp A, Sanal I. Solitary rectal ulcer syndrome: an unusual cause of rectal stricture. Case report. *Chir Ital*. 2001;**53**(4):563-6. [PubMed:11586577]
40. Godbole P, Botterill I, Newell SJ, Sagar PM, Stringer MD. Solitary rectal ulcer syndrome in children. *J R Coll Surg Edinb*. 2000;**45**(6):411-4. [PubMed:11153436]
41. Akaraviputh T, Watanapa P, Ratanarapee S. Solitary rectal ulcer syndrome: two case reports. *J Med Assoc Thai*. 1999;**82**(6):623-7. [PubMed:10443088]
42. Lokuhetty D, de Silva MV, Mudduwa L. Solitary rectal ulcer syndrome (SRUS) masquerading as a carcinomatous stricture. *Ceylon Med J*. 1998;**43**(4):241-2. [PubMed:10355182]
43. Cho NH, Park CI, Ahn HJ. Clinicopathologic comparison of eroded polypoid hyperplasia and solitary rectal ulcer syndrome. *J Korean Med Sci*. 1994;**9**(4):319-27. [PubMed: 7848580]
44. Park HJ, Kim WH, Woo JS, Han KH, Lee SI, Park IS, et al. Solitary rectal ulcer syndrome. *Yonsei Med J*. 1994;**35**(2):223-30. [PubMed: 8091800]
45. Mercer-Jones M, Jenkins R, Garvey C, Norris TL, Hershman MJ. A case of solitary rectal ulcer syndrome. *JR Soc Med*. 1994;**87**(11):708. [PubMed: 7837200]
46. Ingle SB, Patle YG, Murdeshwar HG, Hinge Ingle CR. An unusual case of solitary rectal ulcer syndrome mimicking inflammatory bowel disease and malignancy. *Arab J Gastroenterol*. 2012;**13**(2):102. doi: 10.1016/j.ajg.2012.02.004. [PubMed: 22980604]
47. Li SC, Hamilton SR. Malignant tumors in the rectum simulating solitary rectal ulcer syndrome in endoscopic biopsy specimens. *Am J Surg Pathol*. 1998;**22**(1):106-12. [PubMed: 9422323]
48. Pai RR, Mathai AM, Magar DG, Tantry BV. Solitary rectal ulcer syndrome in childhood. *Trop Gastroenterol*. 2008;**29**(3):177-8. [PubMed:19115614]

49. Delgado J, Delgado B, Sztarkier I, Sperber AD, Walfisch S. A solitary rectal ulcer mimicking rectal cancer. *Gastrointest Endosc.* 2005;**62**(2):309-; discussion 309. [PubMed: 16047005]
50. Lessells AM, Beck JS, Burnett RA, Howatson SR, Lee FD, McLaren KM, et al. Observer variability in the histopathological reporting of abnormal rectal biopsy specimens. *J Clin Pathol.* 1994;**47**(1):48-52. [PubMed: 8132809]
51. Malde HM, Chadha D. Solitary rectal ulcer syndrome: transrectal sonographic findings. *AJR Am J Roentgenol.* 1993;**160**(6):1361-2. doi: 10.2214/ajr.160.6.8498266. [PubMed: 8498266]
52. Halligan S, Sultan A, Rottenberg G, Bartram CI. Endosonography of the anal sphincters in solitary rectal ulcer syndrome. *Int J Colorectal Dis.* 1995;**10**(2):79-82. [PubMed: 7636377]
53. Feczko PJ, O'Connell DJ, Riddell RH, Frank PH. Solitary rectal ulcer syndrome: radiologic manifestations. *AJR Am J Roentgenol.* 1980;**135**(3):499-506. doi: 10.2214/ajr.135.3.499. [PubMed: 6773369]
54. Marshall M, Halligan S, Fotheringham T, Bartram C, Nicholls RJ. Predictive value of internal anal sphincter thickness for diagnosis of rectal intussusception in patients with solitary rectal ulcer syndrome. *Br J Surg.* 2002;**89**(10):1281-5. doi: 10.1046/j.1365-2168.2002.02197.x. [PubMed: 12296897]
55. Simsek A, Yagci G, Gorgulu S, Zeybek N, Kaymakcioglu N, Sen D. Diagnostic features and treatment modalities in solitary rectal ulcer syndrome. *Acta Chir Belg.* 2004;**104**(1):92-6. [PubMed: 15053472]
56. Van Outryve MJ, Pelckmans PA, Fierens H, Van Maercke YM. Transrectal ultrasound study of the pathogenesis of solitary rectal ulcer syndrome. *Gut.* 1993;**34**(10):1422-6. [PubMed: 8244113]
57. Ihnat P, Martinek L, Vavra P, Zonca P. Case report Novel combined approach in the management of non-healing solitary rectal ulcer syndrome-laparoscopic resection rectopexy and transanal endoscopic microsurgery. *Videosurgery Miniinv.* 2015;**10**:295-8.
58. Bishop PR, Nowicki MJ. Nonsurgical Therapy for Solitary Rectal Ulcer Syndrome. *Curr Treat Options Gastroenterol.* 2002;**5**(3):215-23. [PubMed: 12003716]
59. Jarrett ME, Emmanuel AV, Vaizey CJ, Kamm MA. Behavioural therapy (biofeedback) for solitary rectal ulcer syndrome improves symptoms and mucosal blood flow. *Gut.* 2004;**53**(3):368-70. [PubMed: 14960517]
60. Vaizey CJ, Roy AJ, Kamm MA. Prospective evaluation of the treatment of solitary rectal ulcer syndrome with biofeedback. *Gut.* 1997;**41**(6):817-20. [PubMed: 9462216]
61. Swatton A. Solitary rectal ulcer syndrome: physiology and treatment options. *Br J Nurs.* 2009;**18**(21):1312-5. doi: 10.12968/bjon.2009.18.21.45362. [PubMed: 20081680]
62. Meurette G, Siproudhis L, Regenet N, Frampas E, Proux M, Lehur PA. Poor symptomatic relief and quality of life in patients treated for "solitary rectal ulcer syndrome without external rectal prolapse". *Int J Colorectal Dis.* 2008;**23**(5):521-6. doi: 10.1007/s00384-008-0445-9. [PubMed: 18274765]
63. Malouf AJ, Vaizey CJ, Kamm MA. Results of behavioral treatment (biofeedback) for solitary rectal ulcer syndrome. *Dis Colon Rectum.* 2001;**44**(1):72-6. [PubMed: 11805566]
64. Rao SS, Ozturk R, De Ocampo S, Stessman M. Pathophysiology and role of biofeedback therapy in solitary rectal ulcer syndrome. *Am J Gastroenterol.* 2006;**101**(3):613-8. doi: 10.1111/j.1572-0241.2006.00466.x. [PubMed: 16464224]
65. Daniel F, Siproudhis L, Tohme C, Sayegh R. Solitary rectal ulcer: another view of the management algorithm. *Gastrointest Endosc.* 2006;**63**(4):738-9; author reply 739-40. doi: 10.1016/j.gie.2005.12.009. [PubMed: 16564903]
66. da Fonseca LM, Souza Fde L, Arantes V, da Silva RG. Giant refractory solitary rectal ulcer syndrome treated with topical sucralfate. *Int J Colorectal Dis.* 2010;**25**(8):1025-6. doi: 10.1007/s00384-010-0897-6. [PubMed: 20174810]
67. Ibis M, Kurt M, Onal IK, Haznedaroglu IC. Successful management of bleeding due to solitary rectal ulcer via topical application of Ankaferd blood stopper. *J Altern Complement Med.* 2008;**14**(9):1073-4. doi: 10.1089/acm.2008.0314. [PubMed: 19055332]
68. Kumar M, Puri AS, Srivastava R, Yachha SK. Solitary rectal ulcer in a child treated with local sulfasalazine. *Indian Pediatr.* 1994;**31**(12):1553-5. [PubMed: 7875821]
69. Bulut T, Canbay E, Yamaner S, Gulluoglu M, Bugra D. Solitary rectal ulcer syndrome: exploring possible management options. *Int Surg.* 2011;**96**(1):45-50. [PubMed: 21675619]
70. Stoppino V, Cuomo R, Tonti P, Gentile M, De Francesco V, Muscatello N, et al. Argon plasma coagulation of hemorrhagic solitary rectal ulcer syndrome. *J Clin Gastroenterol.* 2003;**37**(5):392-4. [PubMed: 14564186]
71. Somani SK, Ghosh A, Avasthi G, Goyal R, Gupta P. Healing of solitary rectal ulcers with multiple sessions of argon plasma coagulation. *Dig Endosc.* 2010;**22**(2):107-11. doi: 10.1111/j.1443-1661.2010.00941.x. [PubMed: 20447203]
72. Waniczek D, Rdes J, Rudzki MK, Piecuch J, Rubicz N, Arendt J. Effective treatment of solitary rectal ulcer syndrome using argon plasma coagulation. *Prz Gastroenterol.* 2014;**9**(4):249-53. doi: 10.5114/pg.2014.45108. [PubMed: 25276257]
73. Rau BK, Harikrishnan KM, Krishna S. Laser therapy of solitary rectal ulcers: a new concept. *Ann Acad Med Singapore.* 1994;**23**(1):27-8. [PubMed: 8185265]
74. Samalavicius NE, Kildusis E. Hand-assisted laparoscopic suture rectopexy for complete rectal prolapse complicated by a solitary ulcer and obstructed defecation: a case report and review of the literature. *J Med Case Rep.* 2013;**7**:133. doi: 10.1186/1752-1947-7-133. [PubMed: 23718282]
75. Sitzler PJ, Kamm MA, Nicholls RJ, McKee RF. Long-term clinical outcome of surgery for solitary rectal ulcer syndrome. *Br J Surg.* 1998;**85**(9):1246-50. doi: 10.1046/j.1365-2168.1998.00854.x. [PubMed: 9752869]
76. Frizelle FA, Santoro GA, Nivatvong S. Solitary rectal ulcer syndrome: stopping the prolapse heals the ulceration. *G Chir.* 1996;**17**(6-7):320-2. [PubMed: 9241322]
77. Monson JR, Jones NA, Vowden P, Brennan TG. Delorme's operation: the first choice in complete rectal prolapse? *Ann R Coll Surg Engl.* 1986;**68**(3):143-6. [PubMed: 3729263]
78. Evans C, Ong E, Jones OM, Cunningham C, Lindsey I. Laparoscopic ventral rectopexy is effective for solitary rectal ulcer syndrome when associated with rectal prolapse. *Colorectal Dis.* 2014;**16**(3):O112-6. [PubMed: 24678526]
79. Badrek-Amoudi AH, Roe T, Mabey K, Carter H, Mills A, Dixon AR. Laparoscopic ventral mesh rectopexy in the management of solitary rectal ulcer syndrome: a cause for optimism? *Colorectal Dis.* 2013;**15**(5):575-81. doi: 10.1111/codi.12077. [PubMed: 23107777]
80. Beck DE. Surgical Therapy for Colitis Cystica Profunda and Solitary Rectal Ulcer Syndrome. *Curr Treat Options Gastroenterol.* 2002;**5**(3):231-7. [PubMed: 12003718]
81. Bonnard A, Mougnot JP, Ferkdadjji L, Huot O, Aigrain Y, De Lagausie P. Laparoscopic rectopexy for solitary ulcer of rectum syndrome in a child. *Surg Endosc.* 2003;**17**(7):1156-7. doi: 10.1007/s00464-002-4285-3. [PubMed: 12728388]
82. Menekse E, Ozdogan M, Karateke F, Ozyazici S, Demirturk P, Kuvvetli A. Laparoscopic rectopexy for solitary rectal ulcer syndrome without overt rectal prolapse. A case report and review of the literature. *Ann Ital Chir.* 2014;**85**(ePub).
83. Gomes-Ferreira C, Schneider A, Philippe P, Lacreuse I, Becmeur F. Laparoscopic modified Orr-Loygue mesh rectopexy for rectal prolapse in children. *J Pediatr Surg.* 2015;**50**(2):353-5. doi: 10.1016/j.jpedsurg.2014.09.081. [PubMed: 25638636]
84. Tweedie DJ, Varma JS. Long-term outcome of laparoscopic mesh rectopexy for solitary rectal ulcer syndrome. *Colorectal Dis.* 2005;**7**(2):151-5. doi: 10.1111/j.1463-1318.2004.00729.x. [PubMed: 15720353]
85. Marchal F, Bresler L, Brunaud L, Adler SC, Sebbag H, Tortuyaux JM, et al. Solitary rectal ulcer syndrome: a series of 13 patients operated with a mean follow-up of 4.5 years. *Int J Colorectal Dis.* 2001;**16**(4):228-33. [PubMed: 11515682]
86. Koivusalo AI, Pakarinen MP, Rintala RJ. Rectopexy for paediatric rectal prolapse: good outcomes but not without postoperative problems. *Pediatr Surg Int.* 2014;**30**(8):839-45. doi: 10.1007/s00383-014-3534-6. [PubMed: 24990243]
87. Halligan S, Nicholls RJ, Bartram CI. Proctographic changes after rectopexy for solitary rectal ulcer syndrome and preoperative predictive factors for a successful outcome. *Br J Surg.* 1995;**82**(3):314-7. [PubMed: 7795993]